

Femoral Anteversion*

BY STEPHEN B. MURPHY, M.D.†, BOSTON, SHELDON R. SIMON, M.D.‡, COLUMBUS, OHIO, PETER K. KJEWski, PH.D.§, ROBERT H. WILKINSON, M.D.‡, AND N. THORNE GRISCOM, M.D.‡, BOSTON, MASSACHUSETTS

From the Departments of Orthopedic Surgery and Radiology, Children's Hospital Medical Center, Boston; the Department of Orthopedic Surgery, Ohio State University, Columbus; and the Joint Center for Radiation Therapy, Harvard Medical School, Boston

ABSTRACT: Biplane roentgenography, axial roentgenography, and fluoroscopy are the usual roentgenographic methods of measuring femoral anteversion. These methods use a strict geometrical definition of anteversion. The computerized tomography method of measuring anteversion that was developed recently, and is now widely used, does not adhere to the accepted definition of anteversion and has not been tested for accuracy in a large series. In the present study, the widely used computerized-tomography method of measuring anteversion was tested on thirty-two femoral specimens. With that method, anteversion was consistently underestimated by an average of 10 degrees compared with direct measurements and was reproducible only to within ± 3.6 degrees. Therefore, a new method of measuring anteversion using computerized tomography was developed. It was shown to be accurate to ± 1 degree, as tested on the same specimens.

This study demonstrated geometrically why the currently practiced computerized-tomography method of selecting the points that are used to define the axis of the femoral neck is not consistent with geometrical definitions of anteversion. A more accurate method for both defining the axis of the femoral neck and measuring femoral anteversion is described and recommended for clinical use.

The measurement of femoral anteversion is important in the diagnosis and selection of patients for derotational osteotomy. In the past, femoral anteversion has been measured by roentgenography^{4,14} or fluoroscopy¹².

Recently, methods that use cross-sectional computerized-tomography images to measure anteversion directly have been developed^{7,15}. However, there is no documentation of the technique's accuracy. The present study was performed to provide that documentation. A new method of measuring femoral anteversion using computerized to-

mography was developed; it is more accurate and is based on a strict geometrical reconstruction of the angle of anteversion.

Theoretical Considerations

The geometry of the femur and the definition of femoral anteversion were described in detail by Billing in 1954. We used his geometrical constructions, as follows. The long axis of the femur is the line defined by two points: the center of the knee (the centroid of the distal femoral metaphysis on a cross section through the femoral condyles), K, and the center of the base of the femoral neck (the centroid of the femoral diaphysis on a cross section through the base of the femoral neck), O (Fig. 1). The axis of the femoral neck is the line defined by two points: the center of the femoral head, H, and the center of the base of the femoral neck, O. The plane of anteversion is the plane that contains both the long axis of the femur and the axis of the femoral neck. The condylar axis is the line that is parallel to the posterior aspects of the femoral condyles and passes through the center of the knee, K. The condylar plane contains both the long axis of the femur and the condylar axis. The angle of anteversion is the angle in the transverse plane between the plane of anteversion and the condylar plane.

All of the classic methods of measuring anteversion before the advent of computerized tomography were based on the definitions just described. However, while the definition is theoretically sound^{1-3,5,6,8-10,12,13}, the recordings of the points, lines, and planes using roentgenography and fluoroscopy may vary with the expertise of the radiologist and the radiologic technician and with the cooperation and physical limitations of the patient.

In previously described computerized-tomography techniques, the angle of anteversion was the angle between the condylar axis, defined by a transverse image through the distal part of the femur, and an approximation of the axis of the femoral neck as determined on a single image that was made somewhere along the femoral neck^{7,15} (Fig. 2). Since a single image of the femoral neck in the transverse plane is a two-dimensional transverse cross section, theoretically it should not be used to determine the three-dimensional axis of the femoral neck that ordinarily passes obliquely through this transverse section (Fig. 3).

The fundamental problem with the current method of measuring the angle of anteversion using computerized tomography derives from the geometrical fact that the line

* No benefits in any form have been received or will be received from a commercial party related directly or indirectly to the subject of this article. Funds were received in total or partial support of the research or clinical study presented in this article. The funding source was a grant from the Orthopaedic Research and Education Foundation.

† Children's Hospital Medical Center, 300 Longwood Avenue, Boston, Massachusetts 02115.

‡ Department of Orthopedic Surgery, Ohio State University, Columbus, Ohio 43210.

§ Joint Center for Radiation Therapy, Harvard Medical School, Boston, Massachusetts 02115.

that is used as the axis of the femoral neck is not the true axis of the femoral neck. Therefore, the angle of anteversion is not being measured. This problem is discussed in Part IA of this report.

to the most posterior aspect of the condyles; the angle between the two lines is bisected to give the condylar axis' (Fig. 4-D). Each of these four methods yields a different pair of points for defining the condylar axis and the condylar

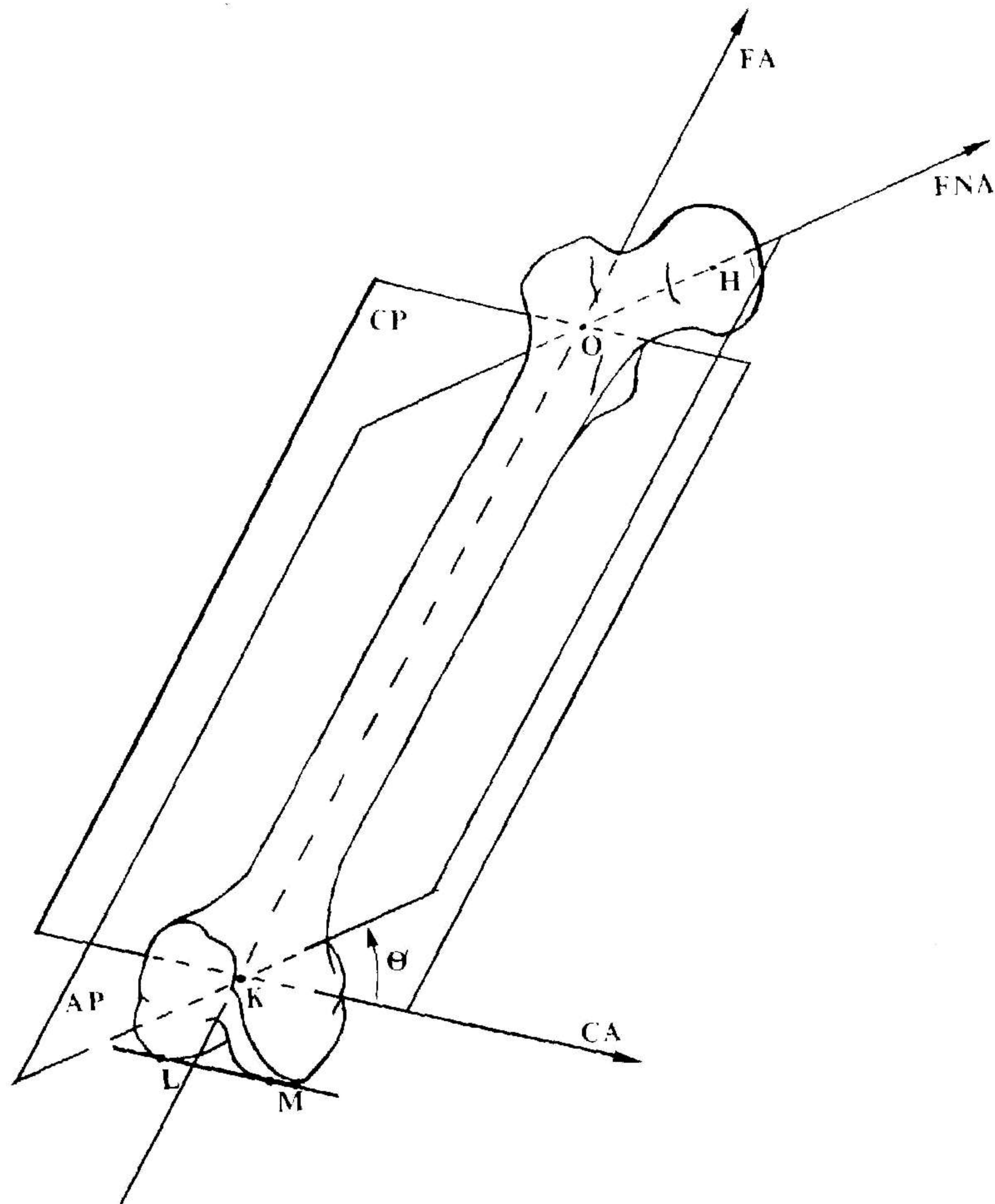


FIG. 1

The femoral axis (FA), the axis of the femoral neck (FNA), and the condylar axis (CA) form the three major reference axes of the femur. These axes define two planes: the condylar plane (CP) and the plane of anteversion (AP). The angle of anteversion (θ) is the angle in the transverse plane between the plane of anteversion and the condylar plane. H = the center of the femoral head, O = the center of the base of the femoral neck, K = the center of the knee, L = the posterior aspect of the lateral condyle, and M = the posterior aspect of the medial condyle. (Adapted from Billing, Lars: Roentgen Examination of the Proximal Femur End in Children and Adolescents. A Standardized Technique Also Suitable for Determination of the Collum-, Anteversion-, and Epiphyseal Angles. A Study of Slipped Epiphysis and Coxa Plana. Acta Radiol., Supplementum 110, 1954.)

Another problem is the determination of the condylar plane. There are four computerized-tomography methods of defining the condylar plane. All four methods use three points to construct the plane. The methods agree in that a point on the long axis of the femur is used, but they differ in the two points that are used to define the condylar axis¹⁵. In one method¹⁵, the condylar axis is defined as the line between the two most posterior aspects of the femoral condyles (Fig. 4-A). (This method is the one that we ultimately chose to use.) For another method, a line is drawn between the most medial and lateral points on the condyles¹⁵ (Fig. 4-B). For a third method, two centroids of the condyles in cross section are visually defined, and the line connecting the centroids defines the condylar axis¹⁵ (Fig. 4-C). The fourth method involves drawing two tangents, one to the most anterior aspect of the femoral condyles and the other




FIG. 2

Current clinical method of determining anteversion using a single transverse computerized-tomography section through the femoral neck (method D), similar to the methods described by Weiner et al. and by Hernandez et al. *a*, For transverse sections that include the femoral head, line AB is drawn from the apparent center of the femoral head to the middle of the isthmus of the femoral neck. *b*, For transverse sections distal to the femoral head, line AB bisects the femoral neck, as it appears on cross section.

plane. Therefore, the angle of anteversion (the angle between the condylar plane and the anteversion plane) will depend on the pair of points that is chosen.

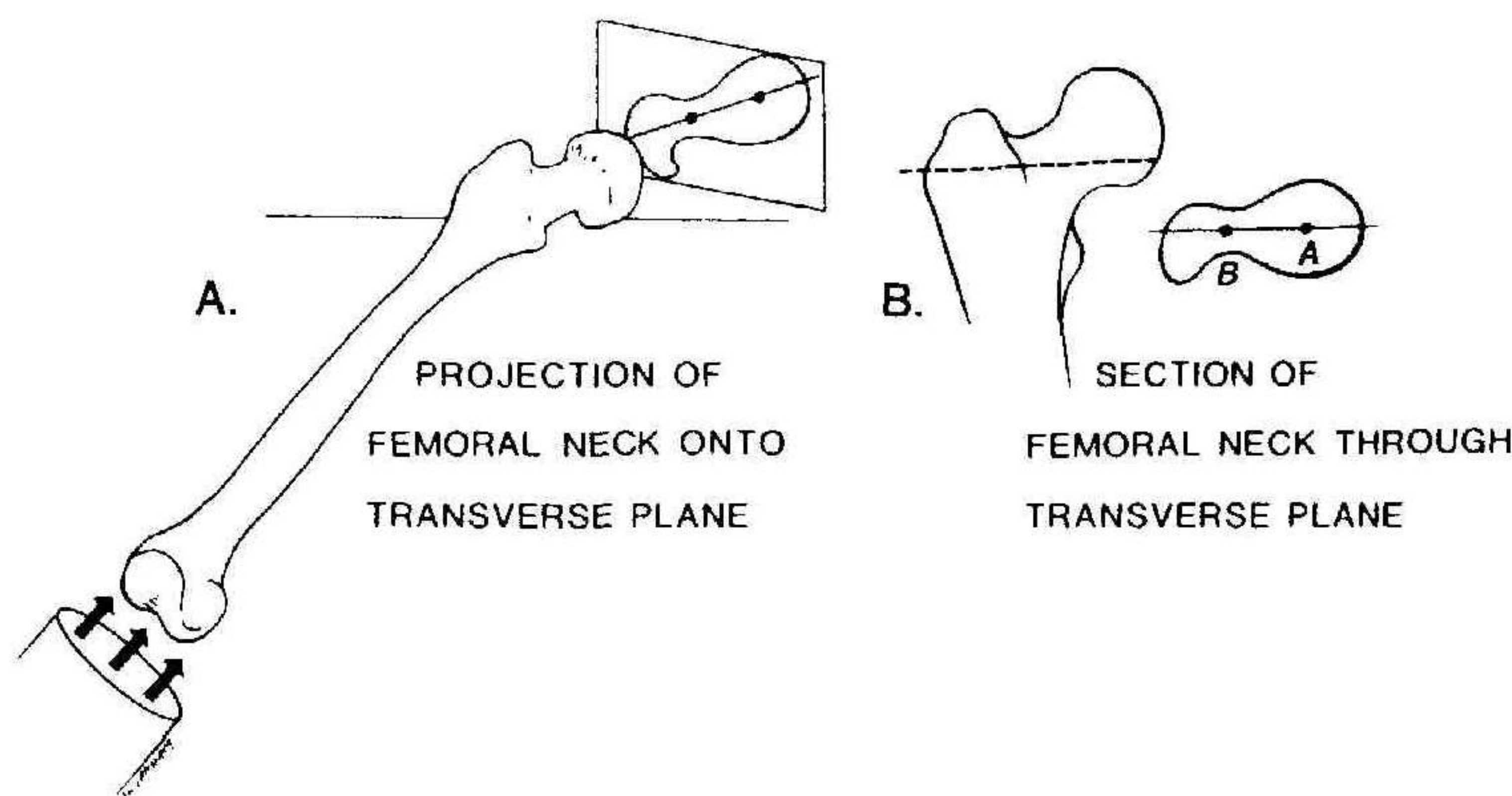


FIG. 3

A, Projection of the neck of a right femur onto the transverse plane. B, Section of the femoral neck through the transverse plane. Only a projection of the femoral neck onto the transverse plane may be used to define anteversion because points H, the center of the femoral head, and O, the center of the base of the femoral neck, have to be used to define the plane of anteversion. A single computerized-tomography image through the femoral neck in the transverse plane may well pass through neither H nor O and therefore has little geometrical basis for defining anteversion. Line AB defines anteversion only if the femoral neck is perfectly cylindrical or if the neck-shaft angle is 90 degrees.

Methods

The first part of the present study was performed to test the accuracy and reproducibility of defining the orientation of the axis of the femoral neck by the computerized tomography method that currently is used clinically (method I). The new method of determining the orientation of the axis of the femoral neck that we have designed (method II) was similarly tested. The second part of the study examined the accuracy and reproducibility of each of the four methods of defining the condylar axis.

Part IA: Measurement of the Axis of the Femoral Neck from Sections

First, method I, the currently practiced computerized-tomography method, was tested by making measurements directly from sections of the femoral neck that simulated computerized tomography images, and by comparing those measurements with a reference plane. Each of twenty adult femora that were taken randomly from cadavera in the anatomical laboratory was placed in a rectangular box-like apparatus. The specimen was aligned so that the axis of the femoral neck, and therefore the plane of anteversion, as determined physically on the bone as a whole, was parallel to the front and back of the apparatus¹. Each bone was then embedded in plaster in the chosen position.

Next, the proximal third of each femur was sectioned transversely, the cuts being made perpendicular to the axis of the femoral shaft. Each cut was made at an interval equal to 1 per cent of the length of the femur (every four to five millimeters). The sections that were obtained are analogous to transverse computerized-tomography images. On each of the transverse sections, method I was used to determine the orientation of the axis of the femoral neck, as depicted in Figure 2. Since the plane of anteversion, as determined physically, was parallel to the sides of the plaster, any difference between the calculated axis using method I and the reference plane could easily be measured.

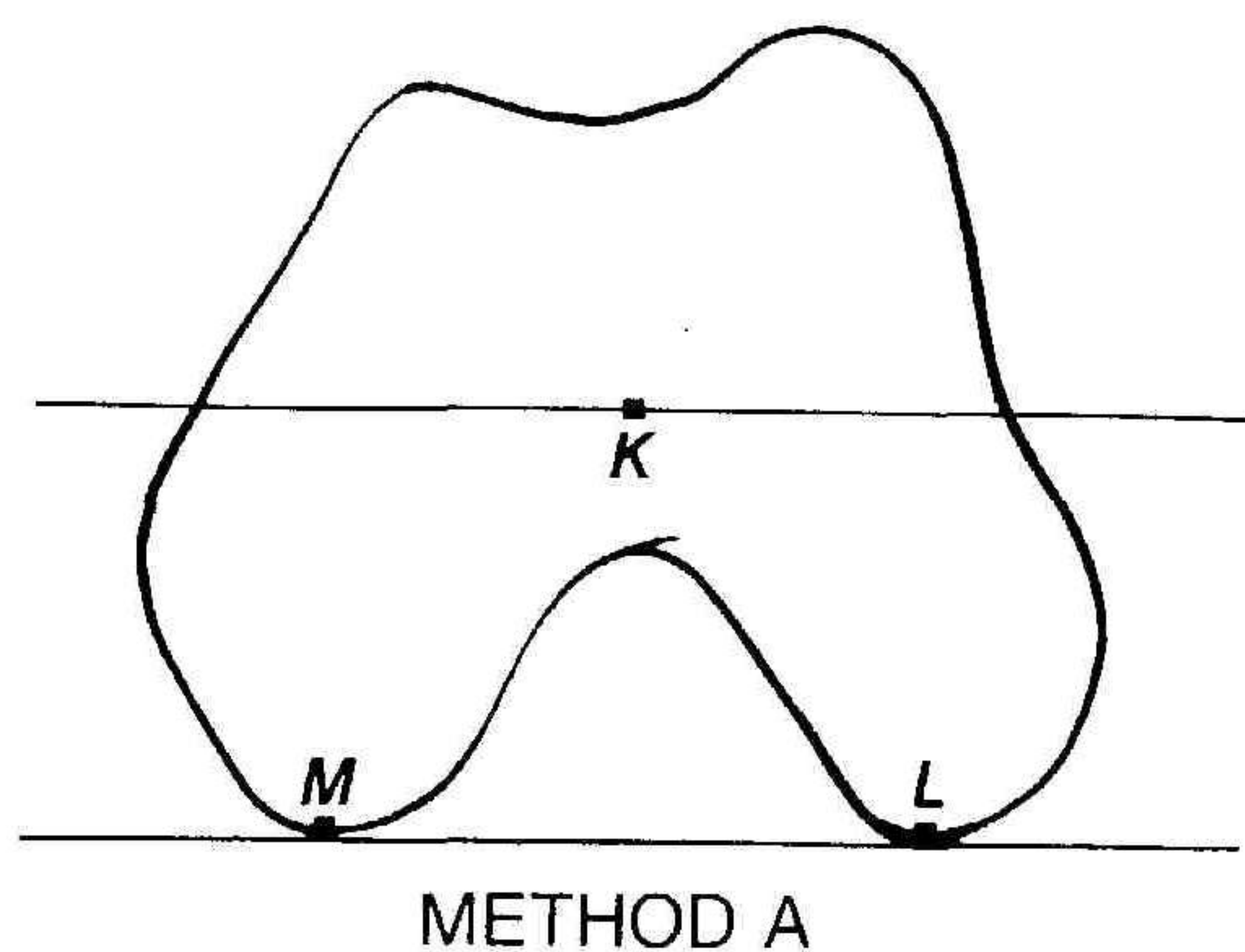
For each transverse section through the femoral neck, the angular difference between the orientation of the axis

of the femoral neck in the transverse plane as measured using method I compared with the reference plane was calculated. The difference between the axis determined by method I and the reference plane was plotted as a function of the longitudinal location of the transverse cut through the femoral neck.

Because of the theoretical inaccuracies of method I, a new method of defining the axis of the femoral neck using computerized tomography (method II) was developed. This method was specifically designed to adhere to Billing's anatomical definitions and to remove any influence of the shape of the femoral neck in cross section on the determination of the axis of the femoral neck. Method II requires two transverse computerized-tomography images, one at each end of the femoral neck, to define the axis of the femoral neck. One image is made through the femoral head to determine point H, the center of the femoral head. A second image is made through the base of the femoral neck to determine point O, the origin of the femoral neck. We defined point O as the centroid of the femoral diaphysis on a cross section through the base of the femoral neck (Fig. 5). Measurements were made directly from sections that simulated the two images. The difference between the orientation of the axis of the femoral neck using method II and the reference plane was then plotted as a function of the longitudinal location of those transverse cuts.

Part IB: Measurement of the Axis of the Femoral Neck Using Computerized Tomography

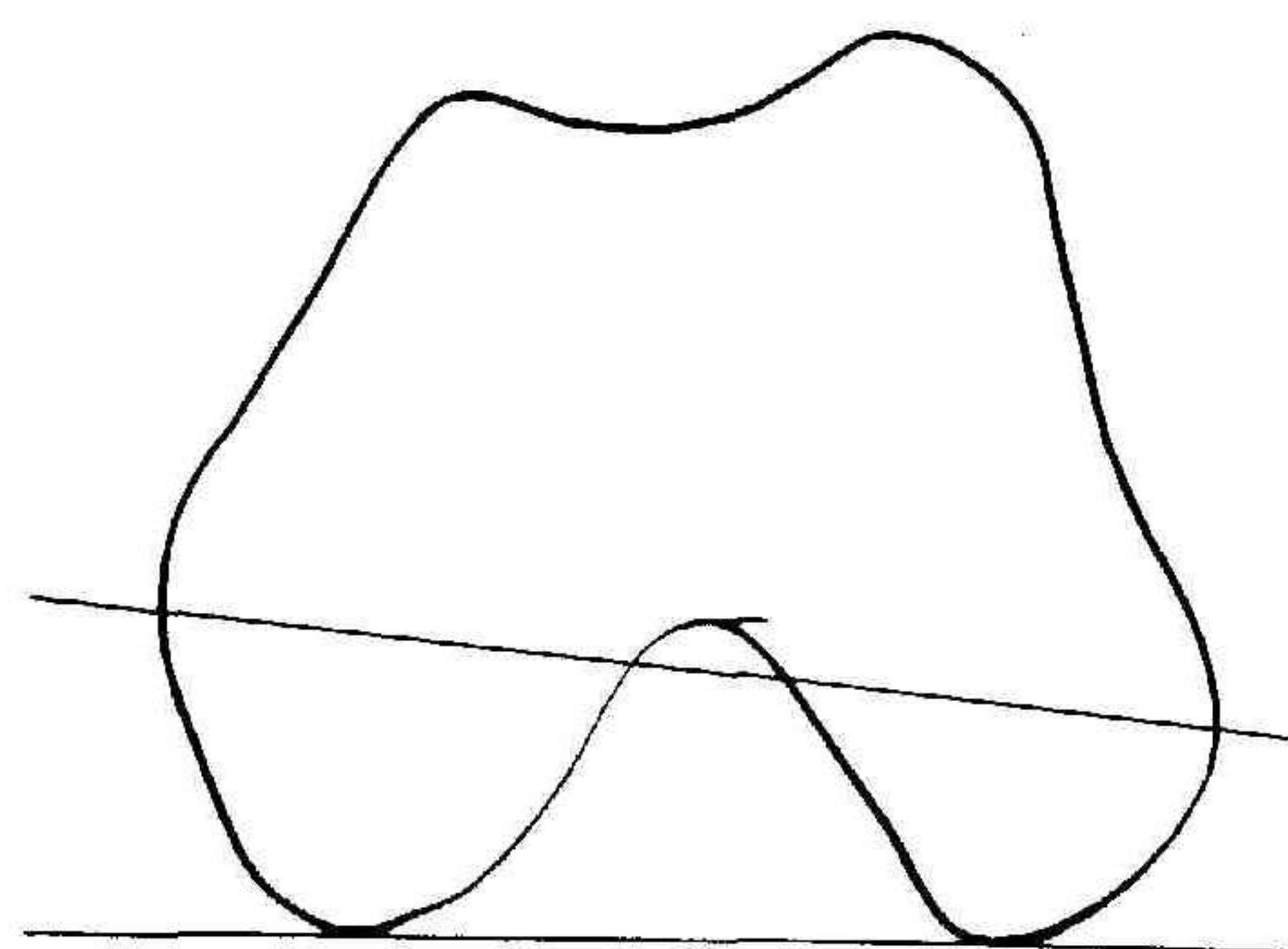
Methods similar to those used in Part IA were used on twelve additional femora from human cadavera using computerized tomography to determine the measurements rather than measuring directly from sections. First, anteversion was measured directly on the twelve femora by eight individuals according to Billing's definitions, and the average of the measurements was used as the reference angle of anteversion. Each femur was then aligned in a General Electric 9800 scanner so that the long axis of the femur was parallel to the long axis of the computerized tomography



METHOD A

Parallel to posterior peaks of condyles

FIG. 4-A



METHOD B

Widest diameter

FIG. 4-B

Figs. 4-A through 4-D: The four computerized-tomography methods for determining the condylar axis. This axis plus a third point on the femoral axis define the condylar plane (see text).

scanner and the condylar plane (as defined by the tabletop method) (Fig. 4-A) was horizontal. The entire head and the neck of each femur were then scanned in serial and contiguous three-millimeter-thick sections.

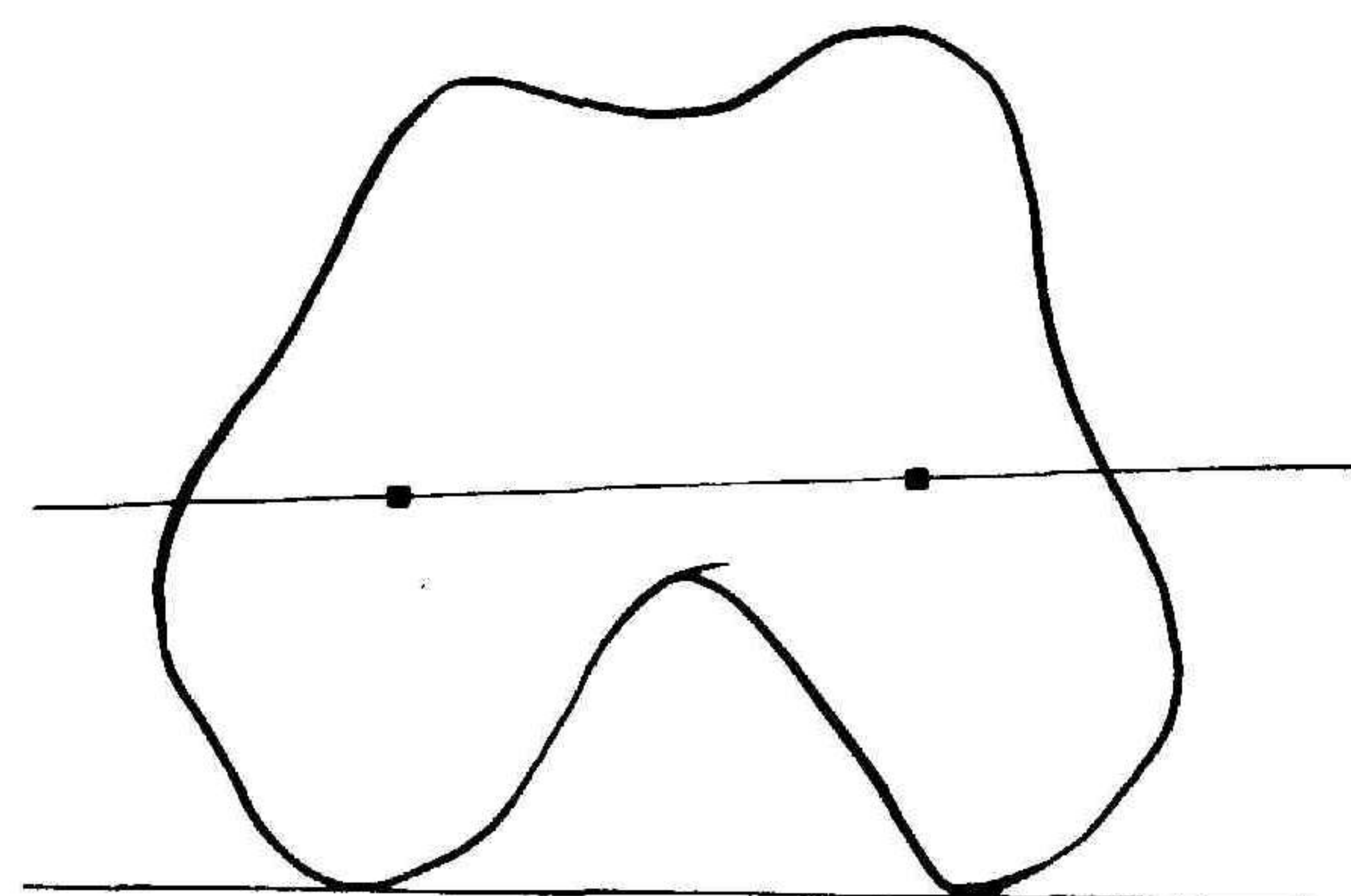
To minimize error in determining the axis of the femoral neck using both method I and method II, the data obtained by computerized tomography were transferred via magnetic tape to a VAX 11/780 computer (Digital Equipment, Maynard, Massachusetts). This allowed magnified computerized-tomography images to be displayed using a Lexidata 3700 image processor (Billerica, Massachusetts). Computer programs, which we wrote ourselves, were then used to draw lines over the computerized tomography images. The observer could rotate and translate these lines into position according to either method I or method II. The angle of the line was then calculated by the computer.

Using this technique, anteversion was measured by both method I and method II, and the results were compared with the reference angle of anteversion. As in Part IA of this study, the measurements were made using both methods over several different levels to test the influence of the location of the slice on the measurement. Finally, to evaluate the reproducibility of each technique, five femora of cadavera were scanned five separate times each and were measured using both methods.

Part II: Measurement of the Condylar Axis and Condylar Plane

Identification of the condylar plane is necessary for the measurement of anteversion. The advent of computerized tomography has resulted in four methods of defining the condylar axis, as will be described.

Method A, the classic tabletop method, defines the condylar axis as the line between the two most posterior aspects of the femoral condyles (Fig. 4-A). Method B, as described by Weiner et al., identifies the most medial and lateral extremes of the condyles. A line between these two points defines the condylar axis. Method C visually defines

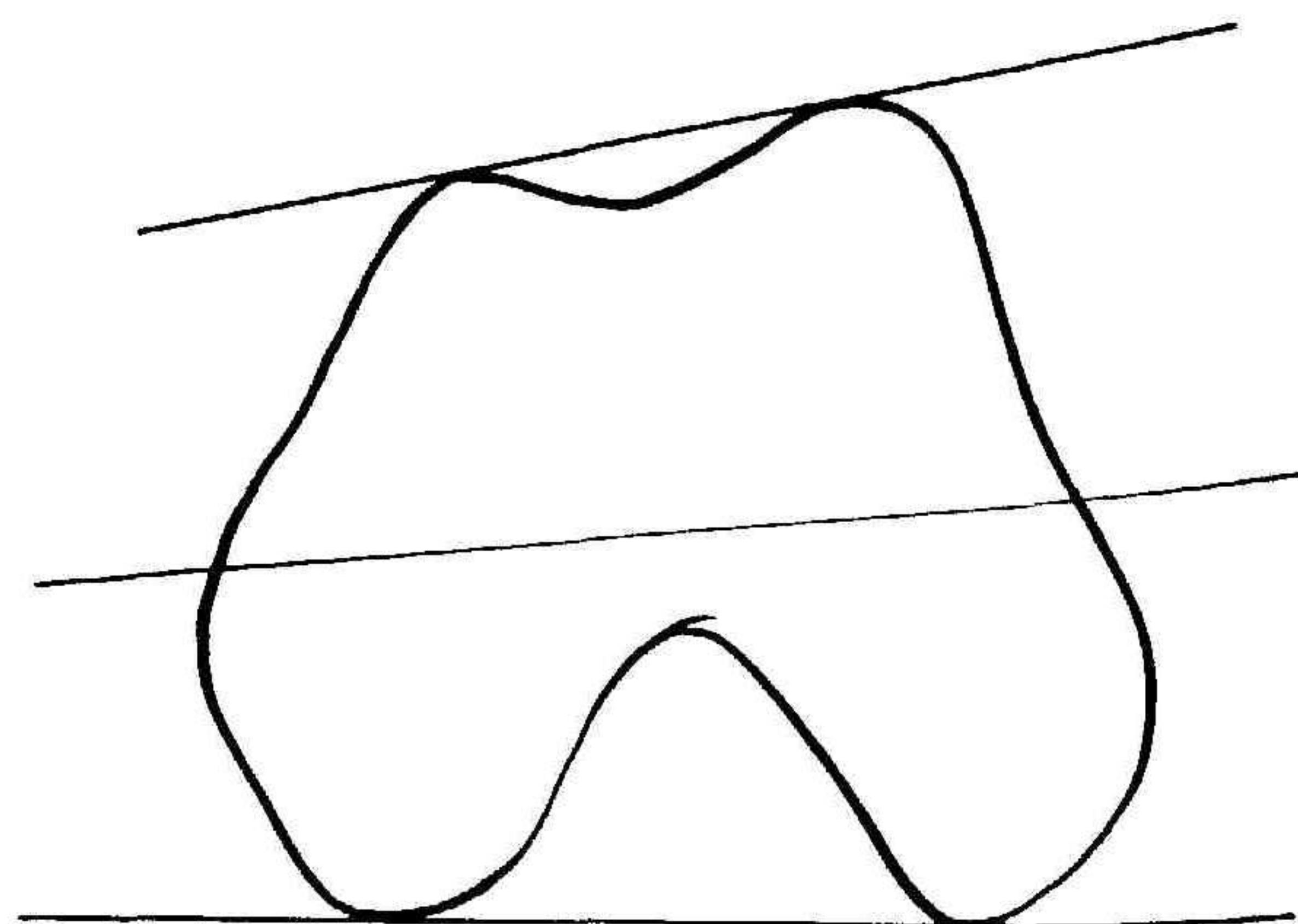


METHOD C

Area centers

FIG. 4-C

Method C.



METHOD D

Bisector of angle between lines connecting anterior and posterior peaks

FIG. 4-D

Method D.

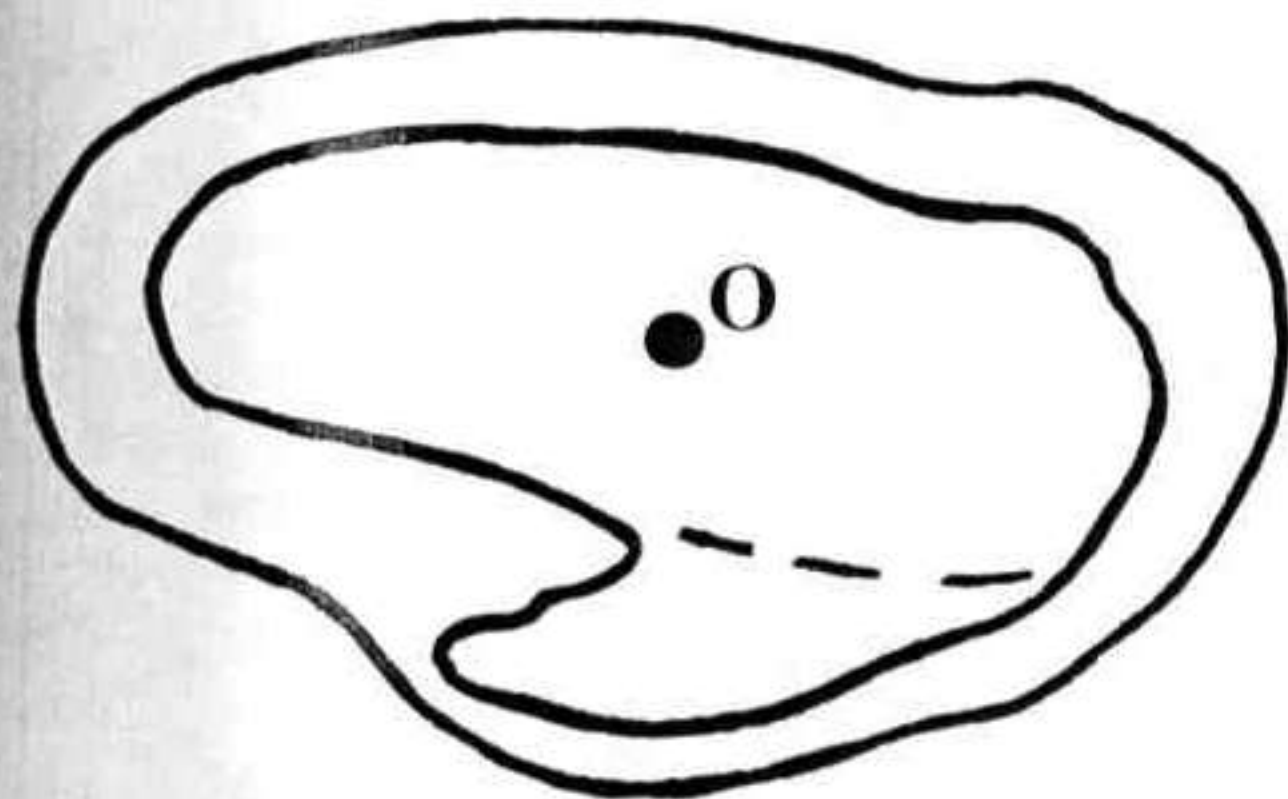


FIG. 5

Point O, the center of the base of the femoral neck, is defined as the centroid of a cross section of the femur at the base of the femoral neck.

the centroids of the medial and lateral condyles on cross section. The line connecting the centroids defines the condylar axis¹⁵. Finally, using method D, as described by Hernandez et al., the axis "is determined by first drawing tangents to the anterior (line a) and posterior (line b) aspects of the femoral condyles. A line is then drawn bisecting the angle between the two lines." This line represents the condylar axis.

To investigate these methods of determining the condylar axis, ten of the twelve femora from human cadavera that were used in Part IB were scanned with the long axis of the femur parallel to the long axis of a General Electric 9800 computerized-tomography scanner and with the posterior aspects of the medial and lateral femoral condyles resting on a horizontal surface. The femoral condyles of each femur were scanned in serial and contiguous three-millimeter-thick sections. The data were transferred via magnetic tape to the VAX 11/780 computer and the images were displayed on a Lexidata 3700 image-display system. Computer-assisted techniques that can define points and measure distances and angles were used to determine the condylar axis by each of the four methods just described. The measurements were made on each of the images through the femoral condyles so that the influence of the location of the slice on each of the methods could be evaluated. Finally, to test reproducibility, the condylar axis was determined using each method on ten separate occasions on a single computerized-tomography image through a bone.

Results

Part IA

Measurement of anteversion by method I, the method in current clinical use, resulted in a consistent underestimation of anteversion (Fig. 6). The underestimation ranged from 18.0 degrees for measurements made from proximal sections of the femoral neck to 6.9 degrees for those made from distal sections. The mean was 13 degrees of underestimation of anteversion (Fig. 6). Representative sections through the femoral head (Fig. 7-A) and the femoral neck (Fig. 7-B) illustrate the results.

Anteversion as determined by method II was under-

estimated by an average of 3 degrees when the section that was used to define point O, the origin of the femoral neck, was 3 per cent proximal to the middle of the lesser trochanter. Anteversion was underestimated by only 0.3 degree when a section that was 3 per cent distal to the middle of the lesser trochanter was used to determine point O. The mean error for all sections was 1.8 degrees less anteversion than the direct measurement (Fig. 6). A representative section through the femur at the base of the femoral neck illustrates the results (Fig. 7-C).

Part IB

Measurements taken from twelve additional femora of cadavera, using computerized tomography, demonstrated similar findings. Method I resulted in an underestimation of the degree of anteversion by a mean of 12 degrees when proximal sections through the femoral neck were used. This error decreased to 6 degrees when distal sections were used. The average error was 9 degrees.

Anteversion as measured by method II was overestimated by an average of only 0.32 degree on sections through the base of the femoral neck that were made six millimeters proximal to the mid-point of the lesser trochanter. The error was even smaller in distal sections (Fig. 8). The mean error, for all sections, was 0.1 degree more anteversion than the reference angle (Fig. 8).

Reproducibility of the two methods was studied using five specimens. Method I had a variance of 13 degrees and a standard deviation of 3.6 degrees. Method II had a vari-

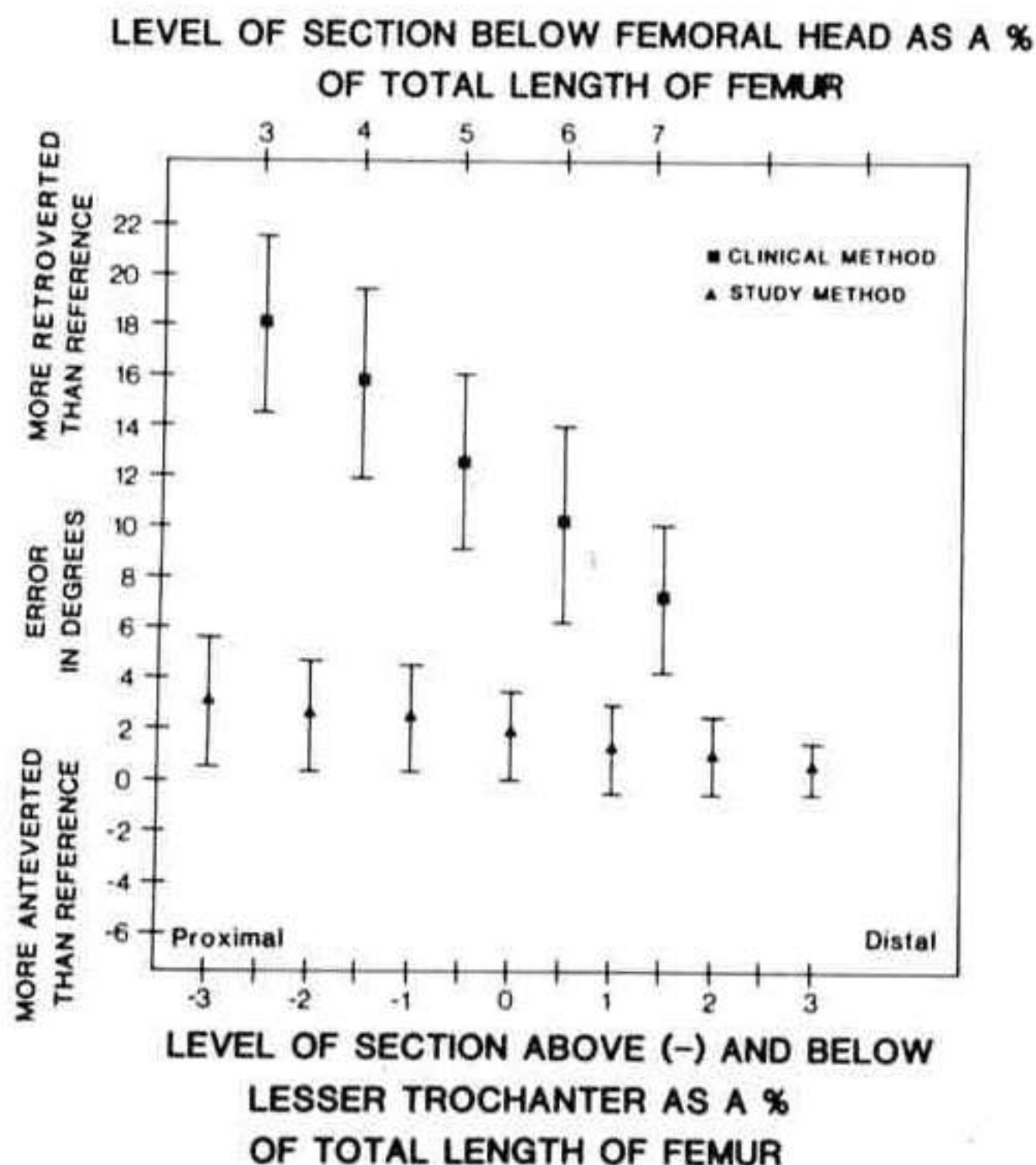


FIG. 6

The differences between the reference angle of anteversion and the angles of anteversion as measured by two computerized-tomography methods, simulated by direct measurement from femoral sections of twenty bones that were embedded in plaster and sectioned. The difference, or error, is plotted as a function of the level of the cross section.

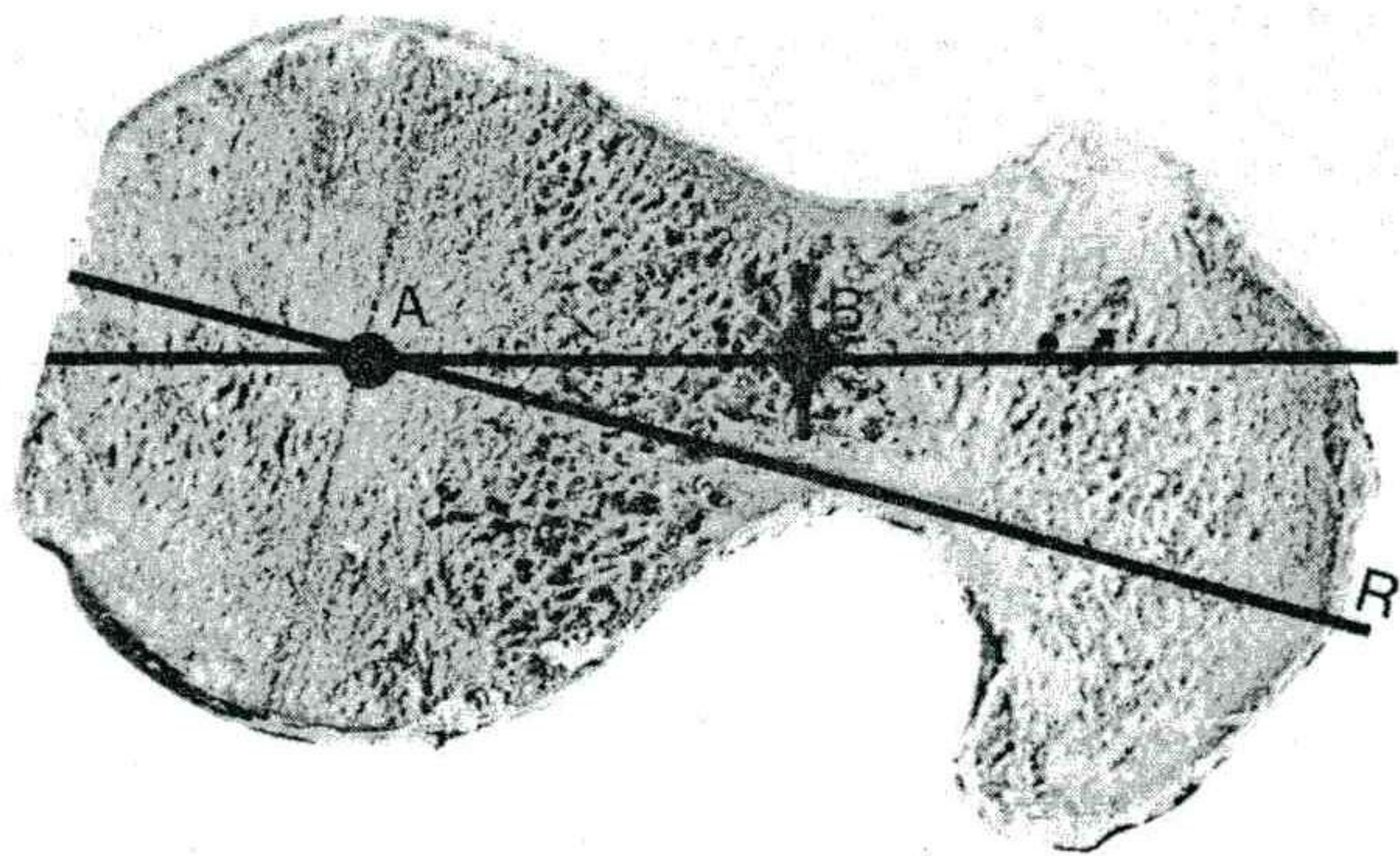


FIG. 7-A

Figs. 7-A, 7-B, and 7-C: Representative cross sections through the femoral neck demonstrating the error in measuring anteversion using method I. The photographs in Figs. 7-A, 7-B, and 7-C were of the same bone.

Fig. 7-A: Measurements from images through the proximal part of the neck demonstrated the largest error. A single image through the proximal part of the neck makes the neck appear to be in neutral position even though the true plane of anteversion, as determined on the bone as a whole (R), is anteverted.

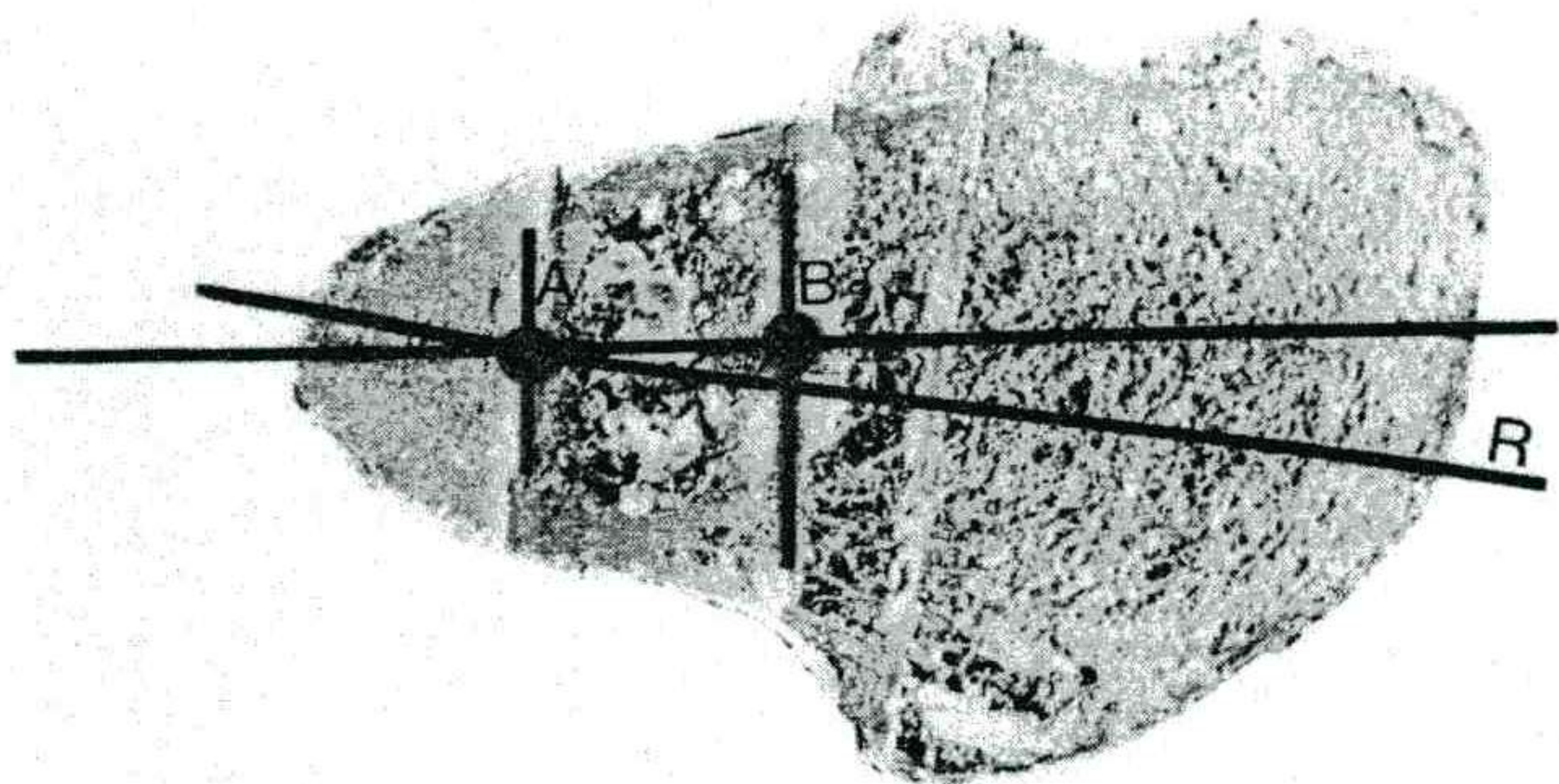


FIG. 7-B

Images through the middle and distal parts of the femoral neck also show the neck to be in neutral position compared with the reference plane of anteversion (R). The error is typically less than for more proximal sections. These sections demonstrate that the method of measuring anteversion that is currently used clinically (method I) not only is inaccurate, but that the measurement is highly dependent on the level of cross section through the femoral neck.

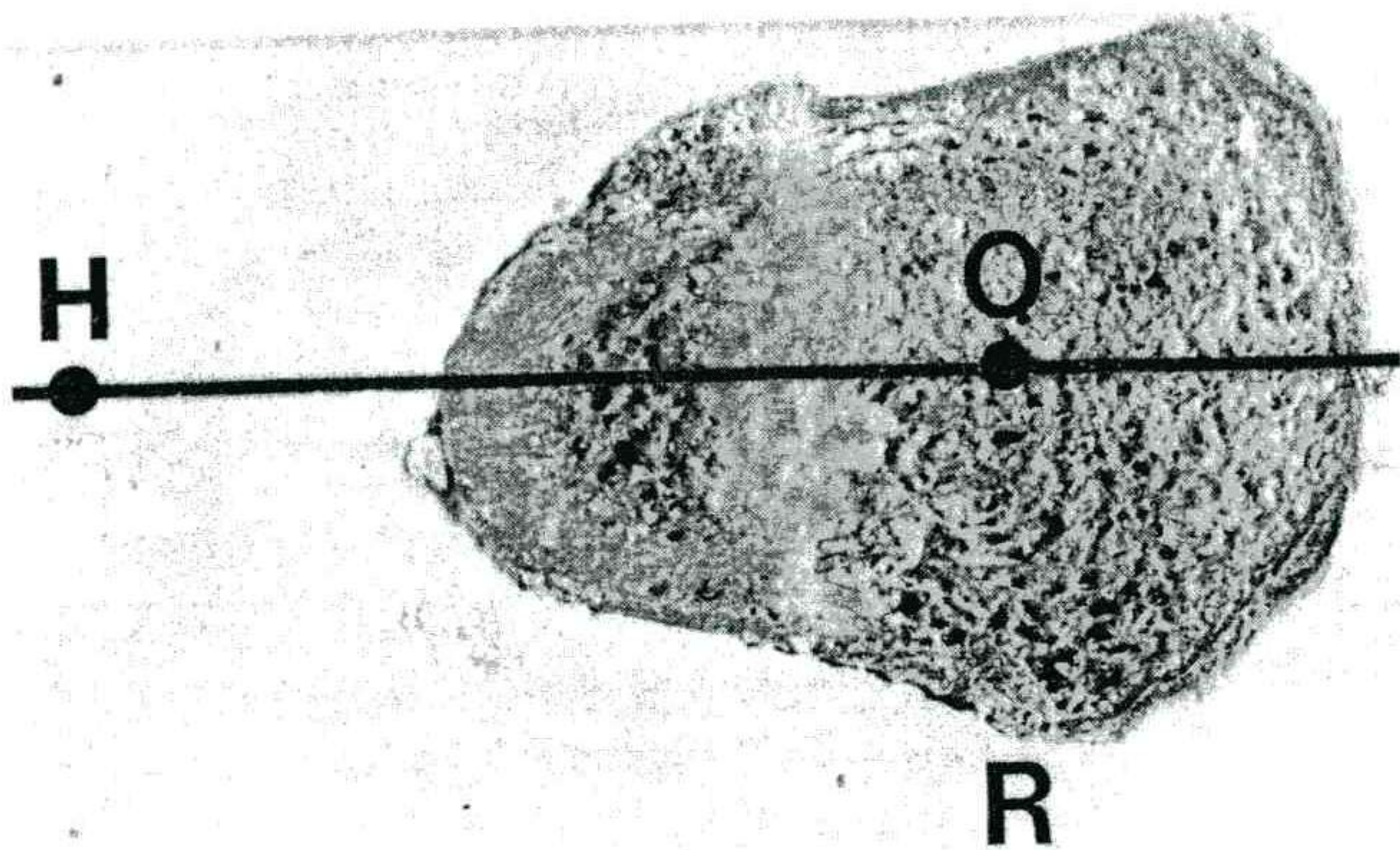


FIG. 7-C

The section through the base of the femoral neck that we used to define point O. Point H is obtained by superimposing the location of the center of the femoral head (determined from another section). Note that the line HO, determined using the proposed method (method II), is horizontal and agrees with the reference anteversion (R).

ance of 0.4 degree and a standard deviation of 0.6 degree.

Part II

Method C (the centroid method) and method A (the tabletop method) were the least influenced by changing the location of the image through the femoral condyles (Fig. 9). The tabletop method (method A) was the most reproducible, with a standard deviation of 0.30 degree. Methods B, C, and D had standard deviations of 1.60 degrees, 1.27 degrees, and 0.40 degree, respectively.

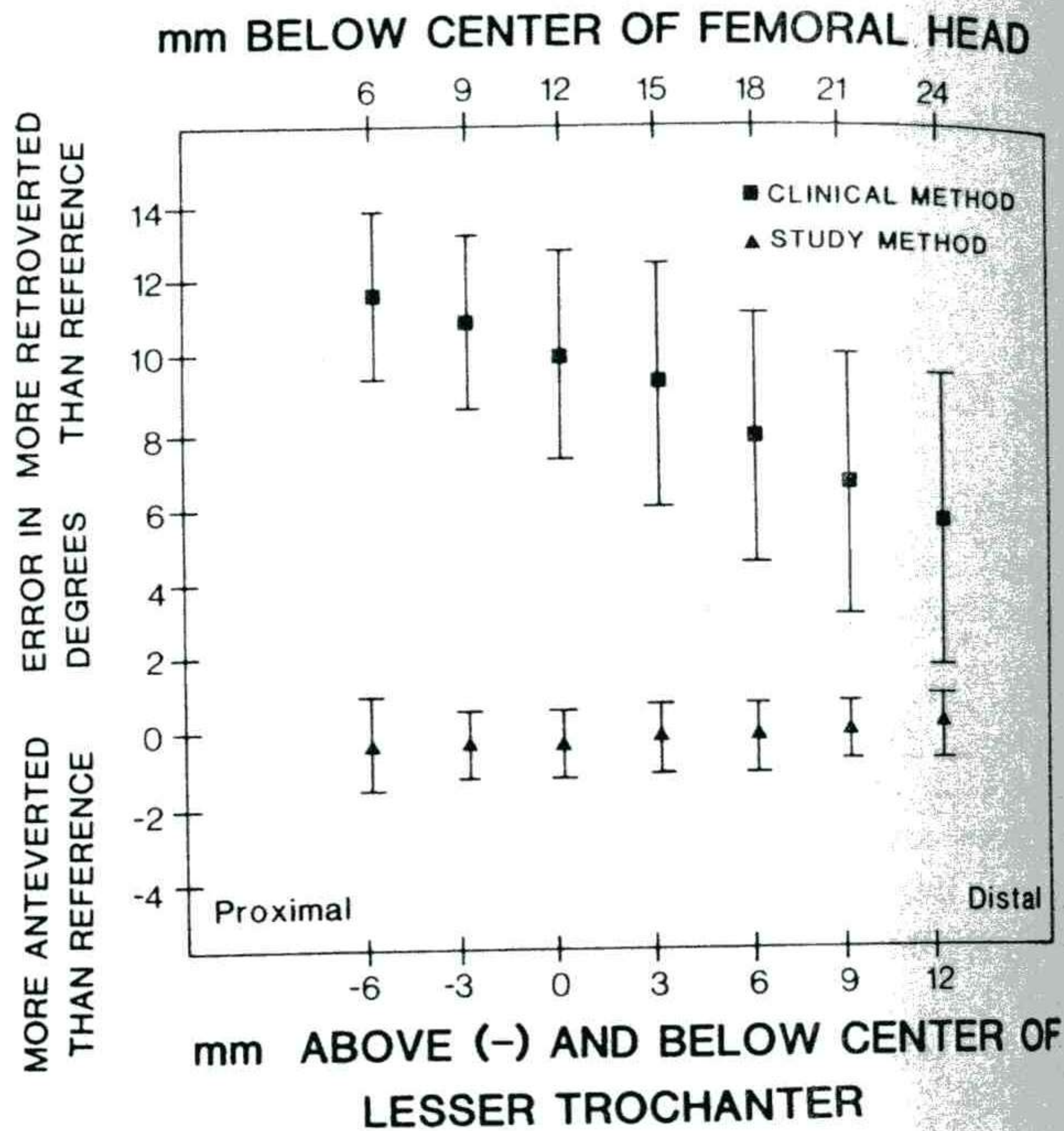


FIG. 8

Angular difference between the reference angle of anteversion and the angle of anteversion using the two computerized-tomography methods in twelve bones. The difference, or error, is plotted as a function of the level of the computerized tomography image.

Discussion

Precise measurement of femoral anteversion is important in the selection of patients for and preoperative planning of derotational osteotomy of the femur. Technical difficulties and the lack of precision of earlier methods have led to the use of computerized tomography to measure anteversion. However, there has not been a study on a large series of bones that documented the reproducibility or accuracy of the currently employed method of measuring femoral anteversion using computerized tomography.

Our study, using measurements made directly from sections of twenty femora and from computerized tomography images of twelve femora, demonstrated that method I (the computerized tomography method that is widely used) underestimates anteversion by about 10 degrees in normal patients. This error was greater for images through the proximal part of the femoral neck and less for images that were made farther distally. The inaccuracies in method I may be explained by the fact that a single section through the fem-

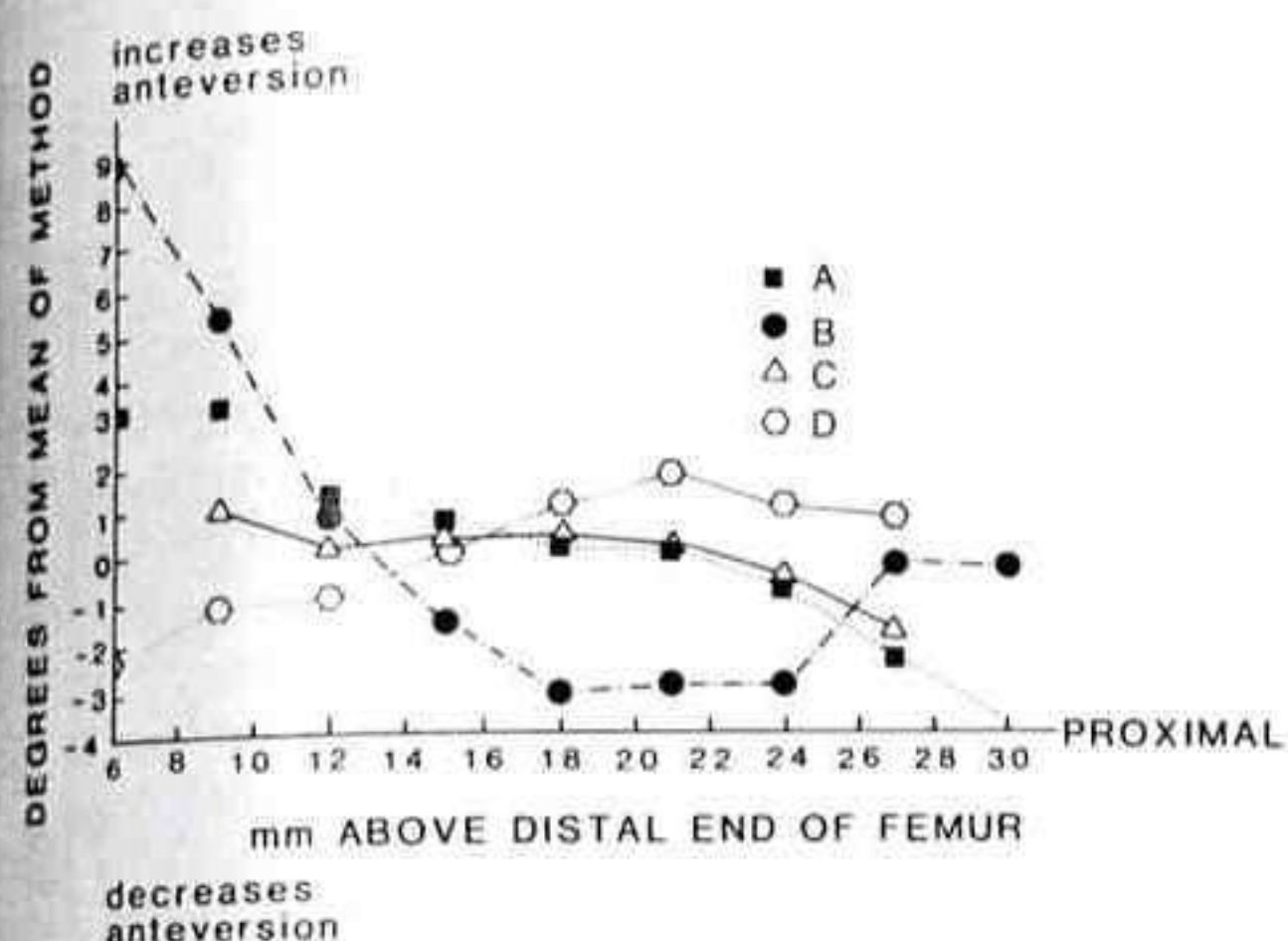


FIG. 9

Summary of the influence of the location of the slice on the determination of the condylar axis by four methods. The results are plotted in degrees of anteversion relative to the mean as determined by that method at all levels studied. Methods A, C, and D resulted in consistent measurements through the mid-portion of the femoral condyles. We chose the tabletop method (method A) because of its simplicity and correlation with the determination of the condylar axis by physical examination.

oral neck often fails to indicate the direction of the axis of the femoral neck. The fact that there is no geometrical basis for this method was recognized by Reikerås et al. To determine the axis, they used two images through the proximal part of the femoral neck: one through the center of the femoral head and a second through the middle of the femoral neck. However, the method of Reikerås et al. has not been widely used clinically.

The finding that method I is inaccurate differs distinctly from the results of two previously reported studies that described that method^{7,15}. The only explanation we can offer is that in both previous studies, the population that was studied was small.

To reduce the inaccuracy of measuring femoral anteversion using computerized tomography, a new method (method II) was developed and tested. This method was specifically designed to overcome the inaccuracies that are inherent in measuring the orientation on a single transverse section through the femoral neck. While this method is similar in principle to that of Reikerås et al., it differs in that the axis of the femoral neck is defined by its endpoints: the center of the femoral head and the base of the femoral neck. This method adheres to the same definition on which

all of the classic anatomical methods of measuring femoral anteversion are based, has been demonstrated to be consistent with classic anatomical measurements to within 2 degrees, and is far less dependent on the position of the transverse images. The method is also reproducible with a standard deviation of 0.6 degree as compared with a standard deviation of 3.6 degrees for method I.

The study of the physically sectioned femora demonstrated larger errors using method I than did the study of femora using computerized tomography. The twenty femora that were physically sectioned were from cadavera that had been donated to Harvard Medical School and were predominantly from white adults. In contrast, the twelve femora that were measured using computerized tomography were from cadavera from India. One possible explanation is that the shape of the femoral neck is slightly different in white adults as compared with Indian adults. The discrepancy between the two study groups was not seen when anteversion was measured using method II, because theoretically this method is independent of the shape of the femoral neck.

In general, all four methods of determining the condylar axis were found to introduce a smaller error into the measurement of anteversion than did the currently practiced method of defining the axis of the femoral neck (method I). The centroid method (method C) was found to be the most consistent method of determining the condylar axis on separate images that were made at different locations through the femoral condyles. The tabletop method (method A) was found to be the second most accurate technique and also the most reproducible one. Therefore, while these two methods are both acceptable, the tabletop method has the best combination of simplicity and reproducibility of measurement not only on the same image, but also on separate images. The tabletop method also has the advantage of theoretically correlating with the clinical method of measurement whereby the knee is flexed 90 degrees, the tibia is vertical, and the condylar plane is assumed to be horizontal. Note that determination of the condylar axis using slices that are too distal results in an overestimation of anteversion, while using slices that are excessively proximal results in an underestimation of anteversion. Therefore, images through the extreme proximal or distal part of the femoral condyle should not be used to determine the condylar axis. The use of thick (for example, ten-millimeter)

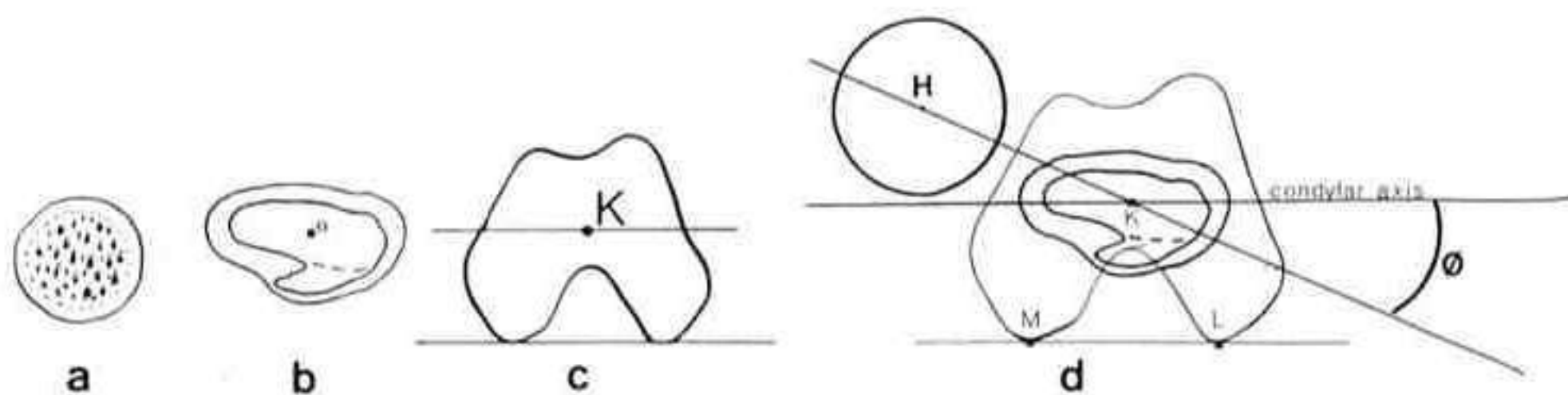


FIG. 10

Summary of the recommended method for measuring anteversion using computerized tomography. The patient is positioned in the scanner such that the long axis of the femur is parallel to the long axis of the scanner. One image (a) defines the location of the center of the femoral head, H. The second image (b) defines the center of the base of the femoral neck, O. The third image (c) defines the condylar axis. The angle in the transverse plane between the intersection of the plane of anteversion (shown as line HO) and the condylar plane defines the angle of anteversion, θ , (d).

computerized-tomography images may minimize the inaccuracies that are introduced by using imaging slices of the extreme proximal or distal part.

To compare methods I and II clinically, nine consecutive patients who underwent either pelvic or femoral osteotomy, or both, were studied. The average age of the patients was thirteen years (range, four to twenty-nine years). The mean and standard deviation of anteversion was 18.0 ± 4.1 degrees using method I as compared with 31.0 ± 4.2 degrees using method II. The average difference between the two methods was 13.0 degrees, which is statistically significant at $p < 0.001$. In the nine hips that had anteversion of more than 30 degrees (using method II), the average underestimation of anteversion using method I was 15.5 degrees compared with method II. This finding suggests that method I, the method that is commonly used to measure anteversion clinically, is least accurate in the patients in whom the measurement is most important.

In summary, we evaluated the accuracy of two methods of determining the axis of the femoral neck and four methods of determining the condylar axis using computerized tomography to determine which is the most accurate and reproducible combination for measuring femoral anteversion using computerized tomography. The current method that is in general use consistently underestimated anteversion. In contrast, the new method (method II) was shown to be both accurate and reproducible and is recommended as the preferred method of measuring femoral anteversion using computerized tomography.

Appendix

Protocol for the Proposed Method of Measuring Anteversion Using Computerized Tomography

The patient is positioned so that the shaft of the femur is parallel to the long axis of the scanner. If the patient has a flexion contracture of the hip, the torso is supported. After generation of an anteroposterior digital radiograph, the position of the three computerized-tomography images is selected: through the center of the femoral head; through the base of the femoral neck; and through the medial and lateral femoral condyles, including the most posterior aspects of the condyles. Each section is at least ten millimeters thick.

The plane of anteversion is defined by drawing a line between the center of the femoral head (first image) and the center of the femoral diaphysis (second image) (Fig. 10). The condylar plane is determined by drawing a line between the posterior aspects of the medial and lateral condyles (third image). The angle between the plane of anteversion and the condylar plane is the angle of anteversion. With many scanners, these measurements can be made directly on the terminal.

Note that an image of the most proximal part of the femoral neck may be substituted for the image through the femoral head if separate anteversion measurements of the head and neck are desired, as might be the case in a patient with slipped capital femoral epiphysis.

NOTE: The authors thank Mary Ann Chin and Carolyn Pickett for assistance with computerized tomography and the Orthopedic Biomechanics Laboratory at the Brigham and Women's Hospital for providing anatomical specimens.

References

1. BILLING, LARS: Roentgen Examination of the Proximal Femur End in Children and Adolescents. A Standardized Technique Also Suitable for Determination of the Collum-, Anteversion-, and Epiphyseal Angles. A Study of Slipped Epiphysis and Coxa Plana. *Acta Radiol., Supplementum* 110, 1954.
2. BRATTSTRÖM, HÅKAN: Two Sources of Error in Measurement of the Anteversion Angle of the Femur. *Acta Orthop. Scandinavica*, 32: 252-256, 1962.
3. DUNLAP, KNOX; SHANDS, A. R., JR.; HOLLISTER, L. C., JR.; GAUL, J. S., JR.; and STREIT, H. A.: A New Method for Determination of Torsion of the Femur. *J. Bone and Joint Surg.*, 35-A: 289-311, April 1953.
4. DUNN, D. M.: Anteversion of the Neck of the Femur. A Method of Measurement. *J. Bone and Joint Surg.*, 34-B(2): 181-186, 1952.
5. EDHOLM, PAUL: Nomogram for Measuring the Anteversion Angle and Angulation of Fracture from Roentgenograms. *Acta Radiol.*, 12: 856-864, 1972.
6. HENRIKSSON, LARS: Measurement of Femoral Neck Anteversion and Inclination. A Radiographic Study in Children. *Acta Orthop. Scandinavica Supplementum* 186, 1980.
7. HERNANDEZ, R. J.; TACHDJIAN, M. O.; POZNANSKI, A. K.; and DIAS, L. S.: CT Determination of Femoral Torsion. *Am. J. Roentgenol.*, 137: 97-101, 1981.
8. MAGILLIGAN, D. J.: Calculation of the Angle of Anteversion by Means of Horizontal Lateral Roentgenography. *J. Bone and Joint Surg.*, 38-A: 1231-1246, Dec. 1956.
9. OGATA, KOSUKE, and GOLDSAND, E. M.: A Simple Biplanar Method of Measuring Femoral Anteversion and Neck-Shaft Angle. *J. Bone and Joint Surg.*, 61-A: 846-851, Sept. 1979.
10. PROUBASTA, I. R.; LLUCH, A. L.; ROIG, J. L.; PALACIO, A. H. M.; CACERES, J. S.; and ARAÑO, R. G.: A New Method of Measuring the Femoral Anteversion and Neck-Shaft Angles. *Clin. Radiol.*, 35: 323-326, 1984.
11. REIKERÅS, O.; BJERKREIM, I.; and KOLBENSTVEDT, A.: Anteversion of the Acetabulum in Patients with Idiopathic Increased Anteversion of the Femoral Neck. *Acta Orthop. Scandinavica*, 53: 847-852, 1982.
12. ROGERS, S. P.: A Method for Determining the Angle of Torsion of the Neck of the Femur. *J. Bone and Joint Surg.*, 13: 821-824, Oct. 1931.
13. RUBY, LEONARD; MITAL, M. A.; O'CONNOR, JOHN; and PATEL, UPENDRA: Anteversion of the Femoral Neck. Comparison of Methods of Measurement in Patients. *J. Bone and Joint Surg.*, 61-A: 46-51, Jan. 1979.
14. RYDER, C. T., and CRANE, LAWRENCE: Measuring Femoral Anteversion. The Problem and a Method. *J. Bone and Joint Surg.*, 35-A: 321-328, April 1953.
15. WEINER, D. S.; COOK, A. J.; HOYT, W. A., JR.; and ORAVEC, C. E.: Computed Tomography in the Measurement of Femoral Anteversion. *Orthopedics*, 1: 299-306, 1978.