

The Role of Hip Arthroscopy in the Elite Athlete

*Joseph McCarthy, MD**; *Wael Barsoum, MD***; *Lalit Puri, MD†*;
*Jo-ann Lee, RN**; *Steven Murphy, MD**; and *Peter Cooke§*

Intraarticular hip disorders in the elite athlete are a relatively rare but serious potential consequence of high-level competition. Axial and torsional forces involving the hips of elite athletes place them at potentially higher risk for chondral injuries, labral injuries, or both. Ten patients (13 hips) had arthroscopy. Of the 10 patients, the average age was 24 years. Nine patients were men and one was a woman. Of the 13 (10 patients) arthroscopies done two cases were bilateral, and one patient had the same hip operated on twice. Seven of the patients were professional hockey players, one patient was a football player, one patient was a baseball player, and one patient was a golfer. All 13 hips (10 patients) had anterior labral tears, whereas two hips had anterior and posterior labral tears. Two hips had an average of four loose bodies, four had evidence of chondral lesions, and one had an anterior margin acetabular fracture. Twelve of 13 arthroscopies were successful; however, one patient had recurrent symptoms. There were no surgical complications. Hip arthroscopy is a safe and reproducible method to diagnose and treat intraarticular hip disor-

ders in athletes, which facilitates earlier return to their respective sport.

Intraarticular disorders of the hip have been receiving increased attention as a potential career-ending problem for the elite athlete.¹ Although such problems are relatively uncommon in the elite athlete, the potential to alleviate mechanical joint symptoms through the judicious use of arthroscopy has been well-documented in the shoulder,¹ wrist,² elbow,³ and knee.⁴ The current authors identified elite athletes competing on either a varsity college team, a national team, or a professional team who had mechanical hip symptoms that did not respond to conservative therapy. These patients tend to subject their hips to a significant amount of stress with increased peak axial and torsional forces because of the nature of their activities. These loads may produce labral and/or chondral injuries to the hip.⁵ In addition, these forces exacerbate what would be considered relatively mild symptoms to the point of rendering the athlete unable to compete. Because conventional radiographs and magnetic resonance imaging (MRI) may be inadequate to observe articular and chondral injuries, direct observation of the joint is advantageous for definitive diagnosis and treatment. If left untreated, there is the potential for additional intraarticular damage because labral and chondral injuries

From the *New England Baptist Hospital, Boston, MA; **The Cleveland Clinic Florida-Naples, Naples, FL; †Northwestern University Medical School, Chicago, IL; and §Hobart College, Geneva, NY.

Reprint requests to Joseph McCarthy, MD, New England Baptist Hospital, 125 Parker Hill Avenue, Boston, MA 02120. Phone: 617-738-6710; Fax: 617-566-2257; E-mail: jlee1@caregroup.harvard.edu.

DOI: 10.1097/01.blo.0000043046.84315.02

have an insufficient blood supply to heal.⁵ The purpose of the current study was to help determine the role of hip arthroscopy in the elite athlete and to show the potential hip injuries to which this patient population is prone and to describe the current authors' treatments and outcomes for this challenging population.

MATERIALS AND METHODS

During a 6-year period, 10 elite athletes (13 hips) were identified from the senior surgeon's prospective database who had arthroscopic hip surgery. In addition, patient charts and operative records were reviewed to document vital statistics, participating sport, levels of competition, surgical findings, and followup either by office visit or questionnaire. Of these 10 patients, nine were men (90%) and one was a woman (10%). The average age of the patients was 24 years (range, 18–35 years). These 10 patients accounted for 13 hip arthroscopies. All patients had outpatient hip arthroscopy in the lateral position using two arthroscopic portals just superior to the greater trochanter.^{3,4} Two patients had one arthroscopic intervention on both hips, whereas one patient had arthroscopy on the same hip on two occasions. Of the 10 athletes, seven were hockey players (70%), one was a football player (10%), one was a baseball player (10%), and one was a golfer (10%).

Any result that allowed the patient to return to his or her preinjury level of competition in a pain-free fashion with no additional surgical or conservative intervention other than standard rehabilitation was considered a successful result. Any patient with continued hip pain or pain that required additional surgical or nonstandardized intervention was considered to have a poor outcome.

RESULTS

The average followup for the 10 patients (13 hips) was 18 months (range, 4 months–6 years). The results of the 10 patients who had arthroscopy showed that there were 11 anterior labral tears (86%) (Fig 1), and two anterior and posterior labral tears (14%). Two of the hips had an average of four loose bodies (range, 2–6) (Fig 2). Four of the 10 patients had some chondral lesion including either chondral flaps (Fig 3) or chondral erosion.

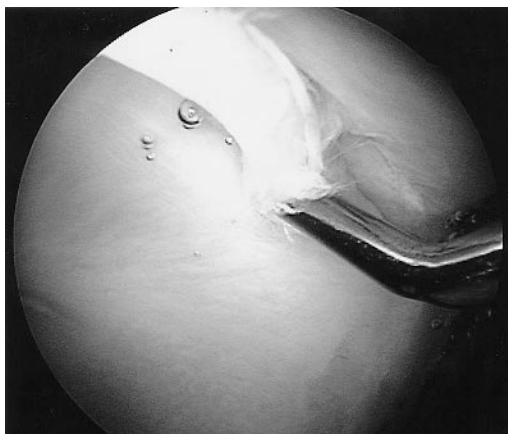


Fig 1. An arthroscopic photograph shows a torn anterior acetabular labrum.

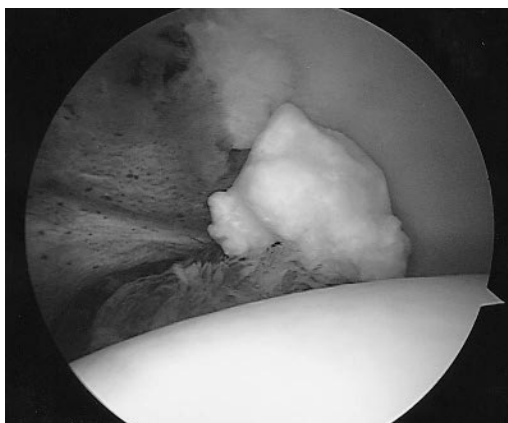


Fig 2. A chondral loose body is shown in the hip.

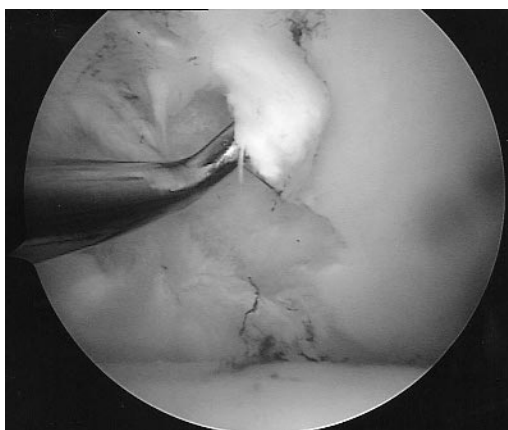


Fig 3. This anterior acetabular articular cartilage shows a chondral flap injury.

TABLE 1. Hip Arthroscopy Findings and Outcome

Patient	Age (years)/ Gender	Sport	Findings	Followup and Result
1	18/Male	Hockey	Torn anterior labrum 2 loose bodies	6 years; excellent
2	27/Male	Baseball	Torn anterior labrum	10 months; excellent
3	22/Male	Football	Anterior + posterior labral tears Synovial impingement Anterior labral Acetabular chondral injury	4 years; excellent
4	27/Male	Hockey	Anterior labral tear Mild synovitis Chondral flap of anterior medial acetabulum	3 years; excellent
5	26/Male	Hockey	Anterior labral tear	1 year; excellent
6	35/Female	Golf	Anterior labral tear Chondral flap of anterior acetabular cartilage	1.5 years; continued pain
7	26/Male	Hockey	6 loose bodies Anterior labral tear	8 months; excellent
8	24/Male	Hockey	Anterior labral tear Dysplasia Posterior lateral labral Fraying Anterior acetabular chondral defect Synovitis	13 months; excellent
9	18/Male	Hockey	Anterior labral tear Anterior labral tear	4 months; hip flexion strain 5 months; MRI negative for labral tear
10	21/Male	Hockey	Anterior labral tear Acetabular rim fragment Anterior labral tear	10 months; excellent

These all were located on the anterior acetabular margin. One of the 10 patients had an acetabular rim fracture. All 10 patients returned to compete in their sport. One patient had an overuse hip flexor strain develop. One additional patient had a second hip arthroscopy for a new injury. There were no surgical or perioperative complications in any of the 10 patients (13 surgeries). A synopsis of hip arthroscopy findings and surgical outcomes is shown in Table 1.

DISCUSSION

Intraarticular disorders in the elite athlete can be disabling and potentially career-threatening. Arthroscopy has been shown to be invaluable in the treatment of various anatomic sites in ath-

letes.^{2,6-8} Dailey and Palmer² reported their promising results of the treatment of triangular fibrocartilage complex tears with arthroscopy. Moskal⁷ published a report on the arthroscopic treatment of posterior impingement of the elbow in athletes. Studies extolling the virtues of arthroscopic treatment of the knees and shoulders of athletes are numerous.^{1,6,8-10} For patients with intraarticular hip disorders, the gold standard of open arthrotomy with anterior dislocation of the hip is foreboding and, for a professional athlete, a potentially career-ending intervention. For elite athletes, the extended disability and potential perioperative surgical complications are of particular concern. Given the fact that with proper distraction, and in experienced hands, hip arthroscopy affords the

surgeon a circumferential view of the hip it is not surprising that hip arthroscopy is gaining popularity and more increased widespread use. The need to minimize surgical risks, recovery time and rehabilitation time is paramount in this patient population.

The repetitious high stress loading of the hips of elite athletes in high torque positions make traumatic injuries more likely and more threatening. Many of the patients in the current study were able to do everyday activities with minimal symptoms, but when competing in their sports at a high level, were absolutely incapacitated before arthroscopy. After surgery, most patients with labral tears resumed successful professional athletic careers. Labral debridements were done using a combination of judicious mechanical shaving and thermal ablation to contour the tissues and to minimize the risks of future soft tissue impingement.

Another potential area of concern for these athletes is the importance of preventing future injury or degeneration of the hips. A recent study showed a clear correlation between the presence of labral disorders and early degenerative changes in the hip.⁵ Four of 10 patients had acetabular chondral lesions and one additional patient had an acetabular margin fracture. It is important to trim back these cartilaginous flaps to a stable margin for two reasons. First, this debridement helps to eliminate the mechanical clicking and catching that patients had preoperatively. Second, with repetitive motion, these untreated flaps may become progressive causing more damage to the surrounding acetabular or labral cartilage, or break away and become a loose body.

The anterior labral injuries prevalent in this patient accounts for mechanical symptoms such as locking, catching, and/or buckling. This potentially could be correlated to a bucket handle meniscal tear in the knee. Increased torsional forces and the repetitive loading of the hip in the

elite athlete can subject the labrum to tensile and compressive forces. Subsequent labral tearing and/or chondral injury left untreated may begin the progressive degeneration of the articular cartilage as has been described previously.⁵

The elite athlete poses a difficult surgical challenge. The goal is to return these patients to competitive sports in as short a period as possible without the risk of additional injury. Hip arthroscopy allows the surgeon to diagnose and treat intraarticular disorders of the entire joint, while minimizing the recovery and rehabilitative phase. Hip arthroscopy is the new gold standard for treating the elite athlete with intractable hip pain with mechanical symptoms.

References

1. Andrews JR: Current concepts in sports medicine: The use of COX-2 specific inhibitors and the emerging trends in arthroscopic surgery. *Orthopedics* 23(Suppl):769-772, 2000.
2. Dailey SW, Palmer AK: The role of arthroscopy in the evaluation and treatment of triangular fibrocartilage complex injuries in athletes. *Hand Clin* 16:461-476, 2000.
3. Glick JM: Hip arthroscopy using the lateral approach. *Instr Course Lect* 37:223-231, 1988.
4. McCarthy J, Day B, Busconi B: Hip arthroscopy: Applications and technique. *J Am Acad Orthop Surg* 3:115-122, 1995.
5. McCarthy J, Noble P, Schuck M, Wright J, Lee J: The role of labral lesions to the development of early degenerative hip disease. *Clin Orthop* 393:25-37, 2001.
6. McCarty EC, Marx RG, Wickiewicz TL: Meniscal tears in the athlete: Operative and nonoperative management. *Phys Med Rehabil Clin North Am* 11:867-880, 2000.
7. Moskal MJ: Arthroscopic treatment of posterior impingement of the elbow in athletes. *Clin Sports Med* 20:11-24, 2001.
8. O'Neill DB: Arthroscopic Bankart repair of anterior detachments of the glenoid labrum: A prospective study. *J Bone Joint Surg* 81A:1357-1366, 1999.
9. Rand JA: The role of arthroscopy in the management of knee injuries in the athlete. *Mayo Clin Proc* 59:77-82, 1984.
10. Tomlinson Jr RJ, Glousman RE: Arthroscopic debridement of glenoid labral tears in athletes. *Arthroscopy* 11:42-51, 1995.